



CODEN [USA]: IAJPB

ISSN: 2349-7750

INDO AMERICAN JOURNAL OF  
**PHARMACEUTICAL SCIENCES**

<http://doi.org/10.5281/zenodo.1069008>Available online at: <http://www.iajps.com>

Research Article

## MODEL AYUSH WELLNESS CLINIC AT PRESIDENT'S ESTATE, INDIA: SUCCESS STORIES

Tushita Thakur<sup>1\*</sup>, Izharul Hasan<sup>2</sup>, L. Janani<sup>3</sup>, R. Manickavasagam<sup>4</sup>, Lubna Fatima<sup>2</sup>, Divya Saraswat<sup>5</sup>, Kanak Soni<sup>5</sup>, Ambika Dhiman<sup>6</sup>, Arun Kumar Bhadula<sup>6</sup>, Ashish Kumar Dixit<sup>1</sup>

<sup>1\*</sup> Homoeopathy Consultant, AYUSH Wellness Clinic, President's Estate, New Delhi, India

<sup>2</sup> Unani Consultant, AYUSH Wellness Clinic, President's Estate, New Delhi, India

<sup>3</sup> Siddha Consultant, AYUSH Wellness Clinic, President's Estate, New Delhi, India

<sup>4</sup> Research Office (Siddha), Deputation - AYUSH Wellness Clinic, President's Estate, New Delhi, India

<sup>5</sup> Yoga & Naturopathy, AYUSH Wellness Clinic, President's Estate, New Delhi, India

<sup>6</sup> Ayurveda Consultant, AYUSH Wellness Clinic, President's Estate, New Delhi, India

### Abstract:

*The Government of India, under Prime Minister Shri Narendra Modi has emphasised increased advocacy of AYUSH system of medicine and establishment of Indian systems of medicine specialty centres. Taking this vision forward, the Rashtrapati Bhavan with help of Ministry of AYUSH, Government of India; established the first AYUSH Wellness Clinic (AWC) of the country at President's Estate in July 2015. The clinic caters to the medical needs of the President, officials of President's Secretariat and residents of the President's Estate; and has treatment facilities in the streams of Ayurveda, Yoga and Naturopathy, Unani, Siddha & Homeopathy. The patient-centered care offered at AWC has made it popular among its beneficiaries. The physicians at AWC have consistently worked had based on classical principles and have given results in all type of acute and chronic diseases. This paper is first in the series of successful case reports at AWC.*

**Keywords:** AYUSH, AYUSH Wellness Clinic, India, Rashtrapati Bhavan, Success stories

### Corresponding author:

**Tushita Thakur,**

Homoeopathy Consultant,

AYUSH Wellness Clinic,

President's Estate, New Delhi,

India

QR code



Please cite this article in press as Tushita Thakur et al., **Model AYUSH Wellness Clinic at President's Estate, India: Success Stories**, Indo Am. J. P. Sci, 2017; 4[11].

**INTRODUCTION:**

Honourable Prime Minister of India, Shri Narendra Modi created AYUSH ministry in November 2014 by elevation of the Department of AYUSH under Ministry of Health and Family Welfare. In recent times, the Government of India has increasingly emphasised establishment of Indian systems of medicine specialty centres. Taking this vision forward, the Rashtrapati Bhavan with help of Ministry of AYUSH established the first AYUSH Wellness Clinic (AWC) of the country with all the five systems under one roof at President's Estate in July 2015. A dilapidated building in the President's Estate was renovated and converted into the AWC. The AWC has treatment facilities in the streams of Ayurveda, Yoga and Naturopathy, Unani, Siddha & Homeopathy. The clinic caters to the medical needs of the President, officials of President's Secretariat and residents of the President's Estate. The holistic patient-centered care offered at AWC has made it popular among its beneficiaries. The physicians at AWC have consistently worked had based on classical principles and have given results in all type of acute and chronic diseases. This paper is first in the series of successful case reports at AWC.

**SUCCESS STORIES****1. Type II Diabetes Mellitus management with Ayurveda**

A 55 year old male patient visited Ayurveda OPD at AWC with uncontrolled NIDDM (Type-II DM)

after taking oral hypoglycaemic agents since 2002. His blood investigations showed HbA1C - 8.8% and Blood sugar Fasting and Post Prandial 230mg/dl & 282 mg/dl respectively. The patient complained of generalized weakness, occasional constipation, burning sensation in hands and feet, excessive thirst and polyuria. The patient was diagnosed and was given treatment for Prameha as per Ayurvedic principles.

**Nidana parivarjana:** Patient was advised to restrict diet containing high calories and high concentration of sugar levels like Potato, rice, carbohydrate, Soft drinks etc.

**Internal Medicines:**

1. Phalatrikadi kashya churnam; 20 ml BD After food
2. Shilajitwadi Loha : 2 tab BD After food
3. Arogyavardhini vati : 1 tab TDS (Three times a day)
4. Chandraprabha vati : 1 tab BD (Twice a day)

**External Applications:** Goghruata lepa- on hands and feet twice a day.

**Follow-up & results:** Within 1 month of treatment patient got relief from most of the symptoms such as Constipation, Generalized weakness, burning sensation in hands and feet. The blood sugar levels are given below in Table 1:

**Table 1: The blood sugar levels before and during treatment**

	<b>Before treatment</b> (Done on <b>05/05/2017</b> )	<b>15 days of treatment</b> (Done on <b>07/08/2017</b> )	<b>As on 18/11/2017</b>
<b>HbA1C</b>	8.8%	7.5%	Yet to be done
<b>Blood sugar – Fasting (mg/dl)</b>	230	132	131
<b>PP (mg/dl)</b>	282	139	135

**2. Osteoarthritis (Bilateral Knee joints) treated with Yoga & Naturopathy**

**Case 1:** A 57 year old house wife visited Yoga & Naturopathy OPD at AWC with complain of pain in B/L knee joints associated with swelling and reduced range of motion. Patient is a known case of Diabetes Mellitus since 4years. There is no family history of any disease. Initially she was suffering from pain in both knee joints while walking, but with time her problem worsened.

**Case 2:** A 49 years old male patient visited Yoga & Naturopathy OPD at AWC with complain of pain in B/L knee joints with increased body weight since past few years, gradual in onset, due to sedentary

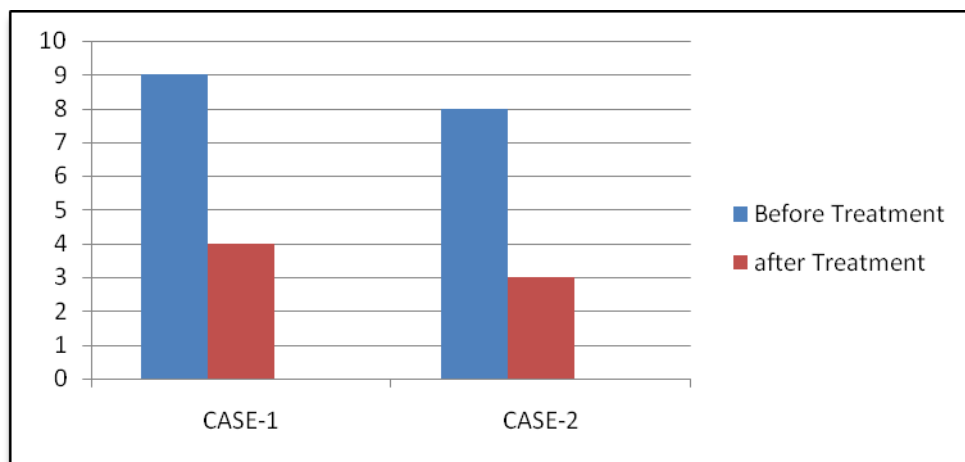
lifestyle. There is no family history of any disease. Initially he was suffering from pain in both knee joints while walking, but with time her problem worsened.

The treatment protocol given to both the patients is mentioned in Table 2.

**Follow-up & Result:** The patient was put on Naturopathic and Yoga treatment for fifteen days with reduction in joint pain and improvement in Range of Movement (ROM). Pain assessment was done with Visual Analogue Scale (Pre & Post) and is given below in Figure 1.

**Table 2: Naturopathy & Yoga protocol prescribed for Osteoarthritis B/L Knee joints**

S No.	Treatment Protocol		Frequency	Duration
1.	Naturopathy	Mustard pack	Daily for 15 days	10 minutes
2.	Yoga Therapy	<ul style="list-style-type: none"> <li>• Sooksm vyayam</li> <li>• Tadasana</li> <li>• Trikonasana</li> <li>• Virkshasana</li> <li>• Uttanpadasana(30 degree with single leg alternately)</li> <li>• Pavanmuktasana (single leg alternately)</li> <li>• Setubandhasana</li> <li>• Makrasana</li> <li>• Bhujangasana</li> <li>• Pranaymas : Surya Anuloma Viloma, Nadishodhana, Kapalabhati, Bhramari</li> <li>• Relaxation technique: IRT, QRT</li> </ul>	Daily for 15 days	30 minutes

**Fig 1: Results of treatment as per VAS (pre- & post)**

### 3. Discoid lateral meniscus tear of right Knee treated with Unani medicine and Wet Cupping Therapy (WCT)

A 19 year old female patient, an athlete by profession visited Unani OPD suffering from right knee joint pain since last 7 months. Her complaints started after forceful twisting of right knee during practice session. She was diagnosed as a case of discoid lateral meniscus tear and underwent Arthroscopic Partial Lateral Menisectomy surgery 7 months back. However, after surgical procedure the patient continued to complain of constant pain

and swelling of right knee joint with limited range of motion preventing her from routine daily activities. The MRI right knee joint showed grade I signal changes seen in posterior horn of lateral meniscus, however no evidence of retraction or discontinuity of the fibre was seen. On examination, there was localized palpable tenderness and diffuse swelling at the joint. Apley's grind test was used to distinguish between meniscal and ligamentous involvement.

**Treatment prescribed:** WCT at right knee once a month, with Majoon Falasfa 10 gm HS daily for 4

months, Arq kasini 100 ml added in 4 litre water and consume in one day everyday for 4 months, local application of medicated paste {Roghan surkh + Nakhoona (Trifolium Indicum) + Ginger} applied locally over right knee joint daily for 30 minutes for 3 months.

**Follow-up & Result:** On 3rd visit patient got 90 percent relief and started to perform routine activities with full range of motion. On 4th visit patient got free from suffering complaints with improvement in quality of life and can perform all routine and athletic activities. This concludes these regimes have excellent clinical results in such cases. The patient was advised to receive WCT once in 3 month as follow up.

#### 4. Management of Metabolic Syndrome through Unani medicine and Venesection

A 61 year old male patient, a known case of Metabolic syndrome visited Unani OPD suffering from Diabetes Mellitus (Type II) and Hypertension since last 10 yrs. The patient was obese (BMI = 39.70 kg/m<sup>2</sup>) and had suffered from uncontrolled

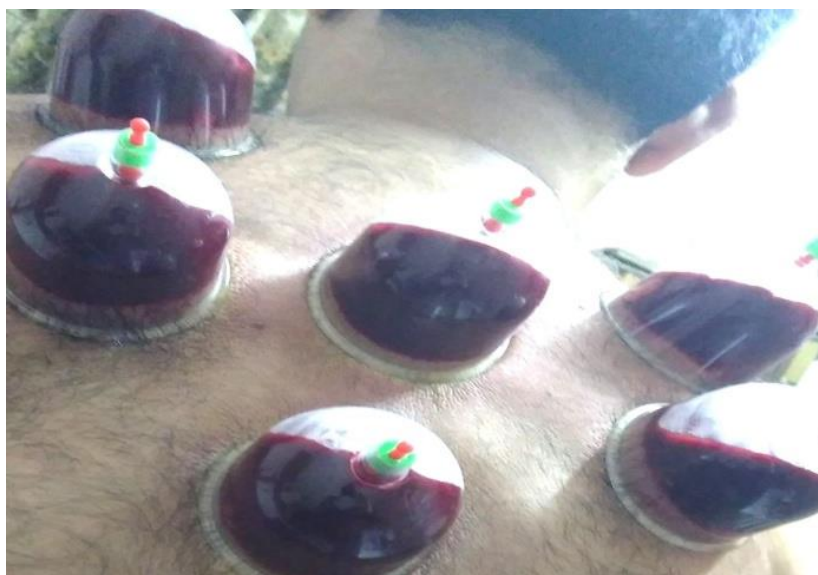blood sugar and blood pressure levels in spite of regular conventional treatment. The patient also complained of edema in left leg up to knees since last two weeks that had made walking difficult for the patient. The patient was thoroughly examined, his BP=194/134 mmHg and Fasting blood sugar=180 mg/dl. Further, laboratory investigations were advised which came out to be GFR 42 ml/minute (moderate to severe decrease) and HBA1C value 7.9 %.

**Treatment prescribed:** Venesection was done twice a month for earlier three months and internal medicine Gokhru powder 6 gram twice a day was prescribed.

**Follow-up & Result:** Significant improvement was observed in all clinical and laboratory parameters as mentioned below in Table 3. Clinically 50% reduction was noticed in edema of right leg after just two sessions of venesection. The patient has been advised regular follow-up at Unani OPD for 6 months to achieve complete remission with full clinical improvement.

**Table 3: Laboratory reports before and 3months into treatment**

	Before treatment	After treatment
<b>HbA1C (%)</b>	7.9	6.0
<b>Fasting blood glucose (mg/dl)</b>	180	132
<b>Systolic BP (mmHg)</b>	194	134
<b>Diastolic BP (mmHg)</b>	134	78
<b>GFR (ml/min)</b>	42	52



**Photo 1: WCT for Shoulder Impingement Syndrome**

### 5. Shoulder Impingement Syndrome treated with Unani medicine and Wet Cupping Therapy (WCT)

A 36 year old male patient visited Unani OPD with complaint of persistent pain in left shoulder affecting everyday activities since last 3 years. Along with left shoulder pain the patient also complained of pain during overhead use of the arm and weakness of shoulder muscles. The patient has been taking conventional treatment of anti-inflammatory/muscle relaxant/steroids medication since long time but was not getting satisfactory relief. A clinical diagnosis of Shoulder Impingement Syndrome was made on basis of medical history, physical examination and for confirmation MRI shoulder was advised. The MRI of left shoulder confirmed the diagnosis and revealed acromion type II erosive arthropathy changes involving the acromion and clavicular ends due to marrow edema with a curved under surface and low lying tilt impinging upon the supraspinatus tendon.

**Treatment prescribed:** WCT (as in Photo 1) was done once a week for four weeks and along with it the patient was advised daily stretching in warm shower thumb up and behind back as auxiliary measures.

**Follow-up & Result:** The patient reported 70% relief in pain on the second visit one week after first session of WCT along with significant improvement in range of movement.

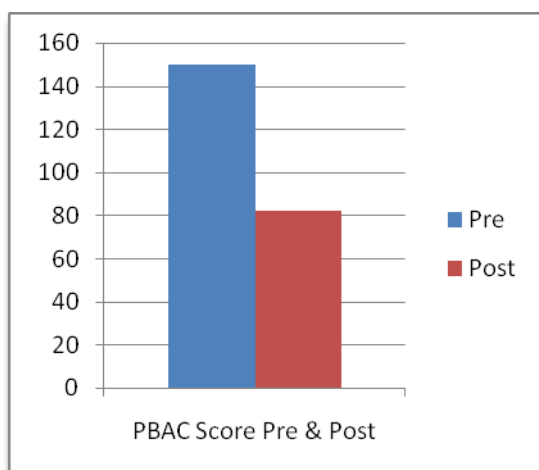


Figure 2: PBAC score (pre- & post)

### 6. Menorrhagia treated with Unani Medicine and Dry Cupping Therapy

A 30 year old female patient visited Unani OPD with complaint of pain abdomen during menses since last 6 years and heavy menstrual flow since 1 year. Her menstrual history is regular, last for 6 days with heavy flow on day 2 to day 4 of cycle, no history of passing clots with Pictorial Blood Assessment Chart (PBAC)-150. The pain abdomen is confined to lower abdomen and usually seen on Day1 of cycle with VAS 8. Patient is married with no issues and using barrier method of contraception for family planning. Patient is not on any type of medication. Ultrasound showed uterus mildly retroverted with 7.3X4X3.1 cm with ET 3.9 mm bilateral ovaries are normal in size and shape. Thyroid profile, bleeding time and clotting time are normal.

**Treatment prescribed:** Dry cupping therapy over breast line and suprapubic region D1 to D 3 of each cycle for 3 consecutive months. Along with cupping; internal medicines- Safoof Surkh 3gm twice a day from Day 2- Day 4 of each cycle for 3 consecutive cycles and Majoon Supari pak 6gm twice a day for rest of the days of month was prescribed.

**Follow-up & Result:** After 3 cycles of cupping therapy patient PBAC comes down to 82 and VAS Score came down from 8 to 2. Patient is relieved up to 70% within 3 months of Unani medicine and therapy. The improvement observed as per PBAC (pre- and post) and VAS (pre- and post) are given below in Figure 2 and Figure 3.

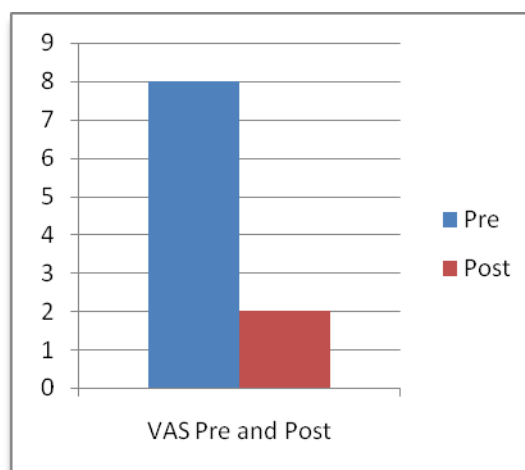


Figure 3: VAS (pre- & post)

### 6. Lumbar Spondylosis treated with Siddha Medicine and Varmam Therapy

A 41 year old male patient visited Siddha OPD with complaint of pain over the lower back radiating to left lower limb along with numbness over left lower limb since last 3 months. His back pain aggravated during walking and standing, and relieved by rest. The pain was shooting in nature with occasional severe cramps felt in calf muscles of left lower limb. The patient was thoroughly examined. On inspection, No scoliosis/ gibbus was observed. On palpation, tenderness was elicited over the lumbo-sacral spinal region. Flexion and extension of spine movements were affected while the lateral flexion was normal. SLR Test, Lassegue's sign, Femoral nerve stretch test and

FABER test were performed before starting treatment.

**Treatment prescribed:** The patient was prescribed Siddha internal medicines for 1 month and Varmam therapy for 48 days. The treatment protocol is mentioned in Table 4.

**Follow-up & Result:** After 48 day Siddha treatment regimen, the patient walks around with no pain in left lower limb and numbness is reduced to a negligible minimum even on walking. The lower back pain, cramps in calf muscles are completely relieved and SLR is negative.

The patient assessment done before and after treatment is given below in Table 5.

**Table4: Siddha treatment protocol prescribed for Lumbar Spondylosis**

S No.	Treatment Protocol		Frequency
1.	Internal medicines	<ul style="list-style-type: none"> <li>• T. Amukkara chooranam (2 tablet thrice a day)</li> <li>• T. Silasathu (2 tablet thrice a day)</li> <li>• Thetran Kotttai Legiyam (5 gm twice a day)</li> <li>• N. V. Kudineer chooranam (5 gm twice a day)</li> </ul>	Daily for 30 days
2.	Varma Points	<ul style="list-style-type: none"> <li>• Komberi kalam</li> <li>• Ulangal vellai Varmam</li> <li>• Mannai Varmam</li> <li>• Ulthodai Varmam</li> <li>• Vayu kalam</li> <li>• Uppukuttri Varmam</li> <li>• Kuthikal varmam</li> </ul>	Daily for 48 days

**Table 5: Physical signs before and after Siddha treatment**

Signs	Before treatment		After treatment	
	Right	Left	Right	Left
SLR Test	+ 40deg	+ 30deg	Negative	Negative
Lassegue's sign	Positive	Positive	Negative	Negative
Femoral nerve stretch test	Negative	Positive	Negative	Negative
FABER test	Negative	Negative	Negative	Negative

### 7. Eczema treated with Siddha Medicine and Patru Therapy

A 27 year old female patient, a house maid visited Siddha OPD with complaint of eczematous lesion on soles of both feet along with intense itching and fissures since last 3 months. Her complaints started suddenly; there was no family history of Eczema or Psoriasis. There is no previous medication history of other diseases.

**Treatment prescribed:** The patient was prescribed Bedhi Therapy with Murukkan Vithai Tablet, two tablets once daily at night with warm water one time along with Chukku Thylam for oil bath twice in a week. Details of internal medicines, external applications and Patru therapy are described in Table 6.

**Table 6: Siddha treatment protocol prescribed for Eczema**

S No.	Treatment Protocol	Frequency
1.	Internal medicines <ul style="list-style-type: none"> <li>• Parangi Pattai chooranam 1gm + Palakarai Parpam 200mg + Irunelli Karpam 200mgs ( Twice a day with hot water, after food)</li> <li>• Rasagandhi Mezhugu Cap (1 O.D at afternoon, after food)</li> </ul>	Daily for 30 days
2.	External applications <ul style="list-style-type: none"> <li>• Karappan Thylam 5 ml at evening</li> <li>• Vanga Vennai 5 gm at night</li> </ul>	Daily for 30 days
3.	Therapy <ul style="list-style-type: none"> <li>• Thiripala Chooranam Patru Therapy</li> </ul>	Daily for 30 days

**Follow-up & Result:** The patient was regularly followed up for Thiripala Chooranam Patru therapy and was completely cured of her complaints as evident from before and after photographs.

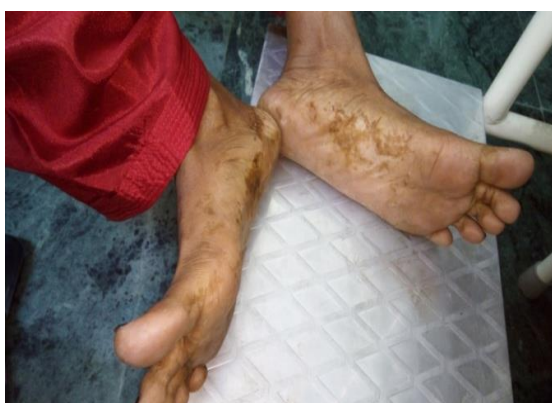

Photo 2: Before treatment

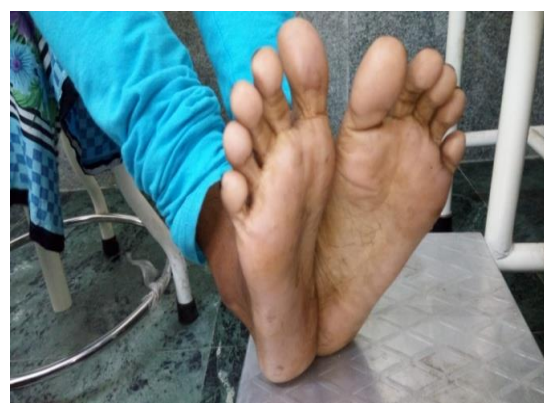

Photo 3: After treatment

### 8. Ulnar nerve palsy/ Ulnar neuropathy treated with Homoeopathy

A 10 year old female patient visited Homoeopathy OPD with complaint of pain down the forearm and the 4th and 5th fingers of right hand along with inability to open right hand fingers completely, inability to move fingers of right had at will and unable to hold anything in the right hand since 1 month. There was also occasional tingling or burning sensation in the right hand. The lack of strength in the hand had affected her daily activities, such as gripping a glass and holding a pen. Her complaints started after suffering from abrasion at lateral side of right forearm near elbow that became infected and lead to abscess formation. The lesion was cut to surgically drain the abscess at nearby Government Hospital. However, the infected lesion was not healed and was being bandaged every alternate day. In the meantime, after the abscess drainage the patient developed the above mentioned symptoms in right hand (Photo 4 and 5).

The case was clinically diagnosed as Ulnar nerve palsy due to: history of blunt trauma near the right elbow; functional and motor impairment; presence of Sign of Benediction; and muscular weakness.

**Treatment prescribed:** The patient was prescribed- Arnica 1M/ unit dose/ stat and Hypericum 30/ thrice a day/ five pills for 15 days. After 15 days on 16/07/2017 the patient reported improvement is visible in photo 6. The second prescription prescribed was Hypericum 30/ thrice a day/ five pills for another 15 days.

**Follow-up & Result:** On 3rd visit on 31/07/17, the patient reported completely recovered from the suffering, can perform all routine activities and has good hand grip. This case confirms the efficacy of Homoeopathic medicines in nerve injuries.

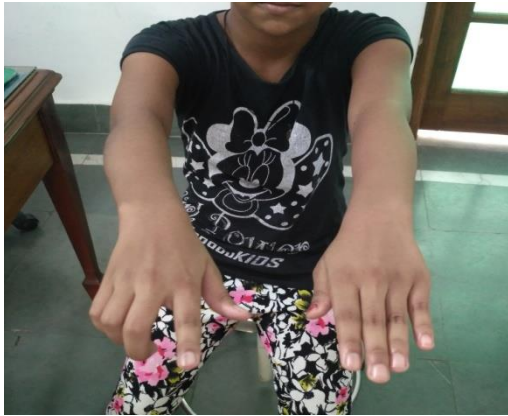

Photo 4: Case presentation (01/07/17)

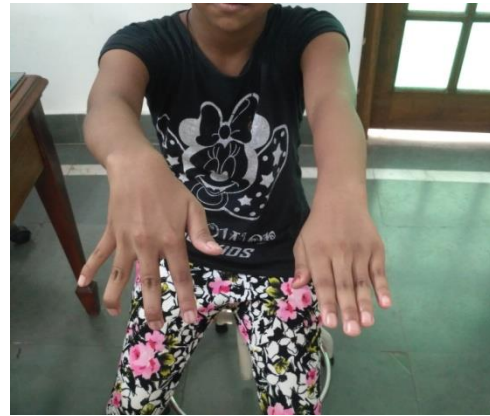

Photo 5: On stretching fingers (01/07/17)

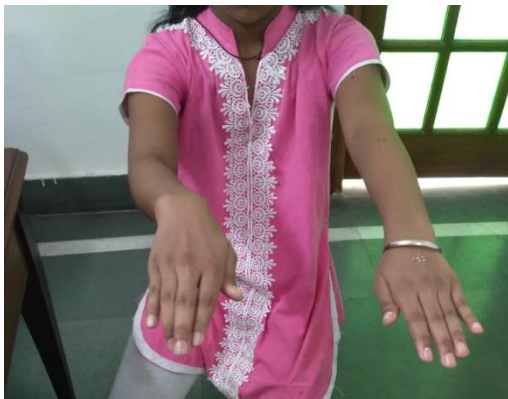

Photo 6: Second visit (16/07/17)

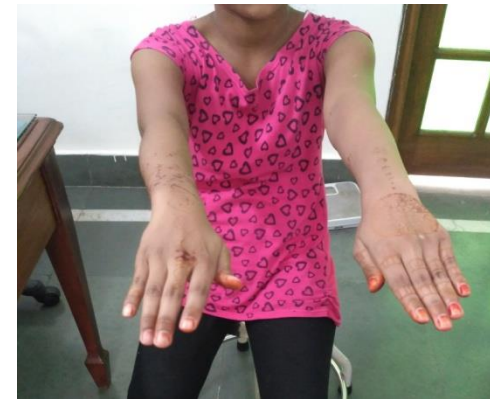

Photo 7: Third visit (31/07/17)

### 9. Lichen Planus treated with Homoeopathy

A 53 year old male patient visited Homoeopathy OPD with complaint of itching on lichenified, papulomatous skin lesion over the flexure surface of left ankle joint since 4 years. Itching was intense and followed by burning afterwards without discharge. Complaints aggravated from sun heat, radiant heat and perspiration, while open air and bathing relieved. Complaints started 4 years ago with appearance of a small itchy papule on left flexure surface of ankle joint without known cause. The patient self-medicated by topical antifungal ointment for sometime before consulting a dermatologist who diagnosed it as a case of Lichen Planus. The symptoms were relieved for a short time after taking allopathy and then relapsed. There was no past history or family history of any skin complaint. Among physical generals- good appetite without desire to eat; bitter taste of mouth when fasting; desire for salt, acid, bitter food and drink; aversion for fatty food and bread; thirst with feeling of dryness of mouth and intake of 2-3 litres water/day. There was profuse sweat over whole body, especially while eating; regular bowels but stools hard, constipated and unsatisfactory with

excoriation of anus. The mental generals of the patient included melancholy sadness, disappointed due to his family affairs, had unpleasant recollections and all attempts at consolation aggravated.

**Treatment prescribed:** On the basis of all mental, physical generals and particular symptoms, and with the help of Repertory, Natrum Muriaticum 200/1dose, in same day evening without taking anything ½ hour before and after followed by Rubrum Metallicum 30/1 drachms 4 pills three times in a day for seven days.

**Follow-up and Results:** Two more doses of Natrum Muriaticum 200 at one month interval from first date of visit and Rubrum Metallicum 30 three times in a day was prescribed for 4 months. In the last visit skin the patient had smooth skin and lesion thickness had flattened without any itching. Patient was assessed from Dermatology Quality of Life Index (DQLI) score on every visit. Baseline DQLI score was 17 and after 4 month of treatment DQLI score was 3.



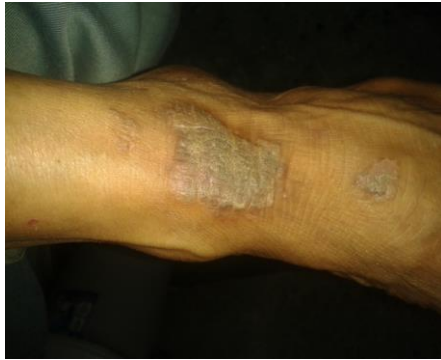

Photo 8: First visit (10/11/15)

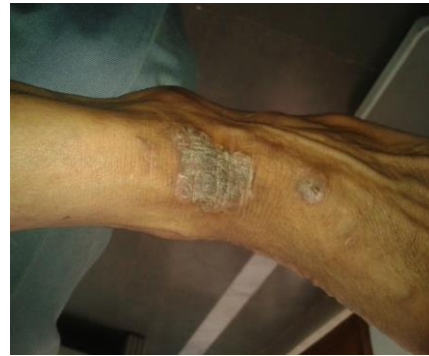

Photo 9: Lesion on 17/12/2015

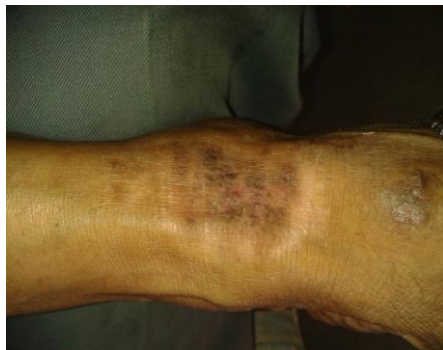

Photo 10: Lesion on 02/02/2016

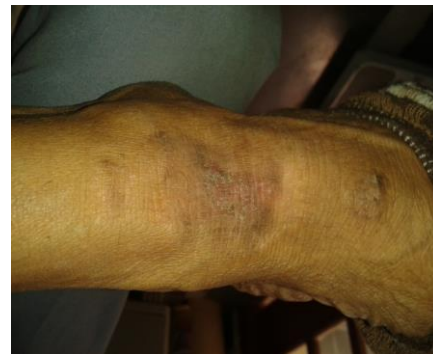

Photo 11: Lesion on 16/02/2016

#### 10. Polycystic Ovarian Disease (PCOD) treated with Homoeopathy

**Table 7: Grading of Acne**

Sign & Symptom	Normal (0)	Mild (1)	Moderate (2)	Severe (3)
Acne (in number)	0	1-3 (1)	4-9 (2)	> 9 (3)
Pain	0	1	2	3
Discoloration	0	1	2	3
Burning	0	1	2	3
Itching	0	1	2	3

A 23 year old female patient, height 160cm and weight 50 Kg visited Homoeopathy OPD with complaint of scanty delayed menses and nodulo-cystic acne on face especially right side since last two years. Her cycles were 35-40days/ 3 days with scanty flow. Her menarche was at the age of 15 years and menstrual cycle was regular with normal flow till two years ago when her complaints started. The patient was more concerned about her acne and had taken lot of oral medicines, used topical applications without much relief. There was cyclic aggravation in acne during menses and the lesions had purplish hue leaving circumscribed spots after drying. Routine investigations with USG lower abdomen was advised which revealed bilateral multiple cysts in ovaries suggestive of Polycystic Ovarian Disease. On further case taking, patient reported hot thermal reaction, reduced appetite, stress due to bad appearance, and desire to drink coffee which she took 4-5 times in a day. The grading of acne was done at start of treatment based on criteria given in Table 7.

**Treatment prescribed:** On the basis of all mental, physical generals and particular symptoms, the following rubrics were taken for repertorisation:

1. Menses: scanty (Complete repertory, chapter female genitalia)
2. Tumor, cyst, ovaries (Complete repertory, chapter female genitalia)
3. Appetite diminished (Complete repertory, chapter stomach)
4. Desire coffee (Kent repertory, chapter stomach)
5. Looks, appearance concerned about (Complete repertory, chapter Mind)
6. Spots, circumscribed after inflammation (Complete repertory, chapter Skin)
7. Food and Drinks, artificial aggravate (Complete repertory, chapter Generalities)
8. Eruptions, pimples right (Complete repertory, chapter Face)

The reportorial result was- Lycopodium 15/5, Arsenicum album 14/6, Lachesis 14/6 and Sulphur

15/5. Lachesis was considered suitable for prescription as it covered following symptoms of the patients – Right sided (acne), ovarian cyst, hot thermal reaction, purplish discoloration of skin lesion. Lachesis 200/1dose, next day morning empty stomach followed by Rubrum Metallicum 30/1 drachms 4 pills three times in a day for 15 days.

**Follow-up and Results:** One dose of Lachesis 200 was given every 15 days followed by Rubrum

Metallicum 30/1 drachms 4 pills three times in a day. Her menses became more regular with 30-35 days cycle and flow also became normal after continuing treatment for 3 months. The same treatment was further continued for another 3 month. USG lower abdomen done at end of six months of treatment reported normal scan. The patient has better appetite; her acne and hyperpigmentation marks are much reduced (Table 8).

**Table 8: Grading of Acne**

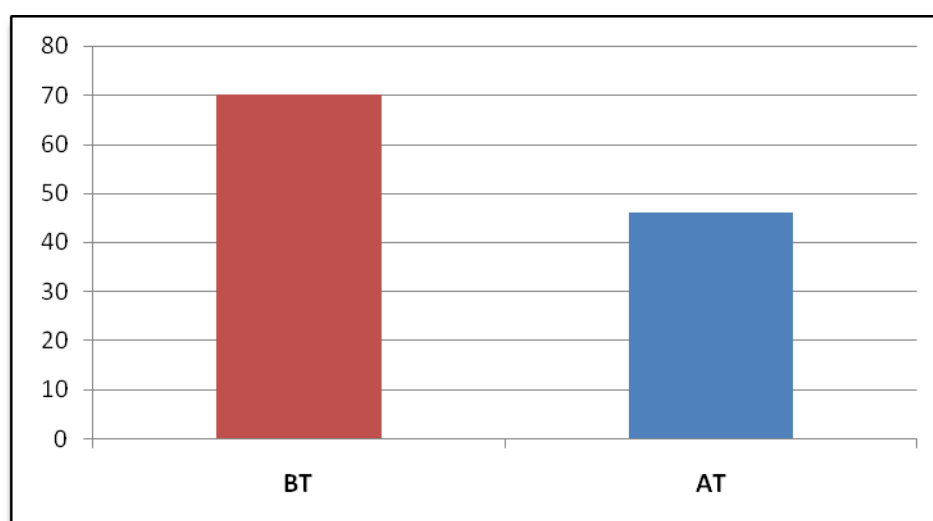
Sign & Symptom	Before treatment	After treatment
Acne (in number)	3	1
Pain	3	0
Discoloration	3	1
Burning	0	0
Itching	1	0

#### 10. Migraine treated with Homoeopathy

A 47 year old female patient visited Homoeopathy OPD with complaint of episodes of alternate side headache with nausea that was relieved by vomiting since last four years. Her complaints started suddenly four years ago and she took allopathy with temporary relief. The patient gave family history of Migraine in her mother and sister. The patient was flabby weighing 68 kg, her BP was normal and she was not taking any other medicine. On further case taking, patient reported chilly thermal reaction, increased perspiration especially on head, episodic hyperacidity and aversion to fats. She had recurrent upper respiratory infections that settled in throat with tonsillitis. The HIT-6 (Headache Impact Test) score done at start of treatment was

**Treatment prescribed:** On the basis of all mental, physical generals and particular symptoms, and with the help of Repertory, Calcarea Carbonica 200/1dose, next day morning empty stomach followed by Rubrum Metallicum 30/1 drachms 4 pills three times in a day for 7 days.

**Follow-up and Results:** One dose of Calcarea Carbonica 200 was given every 7 days followed by Rubrum Metallicum 30/1 drachms 4 pills three times in a day. The frequency and intensity of migraine episodes reduced considerably with much relief of patient as evident in Figure 4. The quality of life of patient has improved and she is able to attend her work regularly.



**Fig 4: HIT-6 Score before and at 6 months of treatment**

**ACKNOWLEDGEMENT:**

We gratefully acknowledge Mrs. Anjali BM Bakshi, Joint Director, Rashtrapati Bhavan for her constant encouragement and support to carry out this work. We offer our sincere thanks to Dr. V K Shahi, A.D. (Ay), CCRAS, Ministry of AYUSH & Co-ordinating officer, AWC, Rashtrapati Bhavan for his guidance. We also thank therapists, pharmacists and staff members of AYUSH Wellness Clinic for their contribution in this work.

**CONFLICT OF INTEREST**

The authors declare that there is no conflict of interest.

**REFERENCES:**

1. Press Information Bureau, Government of India, President's Secretariat. President of India to inaugurate AYUSH wellness clinic at President's Estate. Available at: <http://pib.nic.in/newsite/PrintRelease.aspx?relid=123676>. Accessed on 09/11/2017.
2. Press Information Bureau, Government of India, President's Secretariat. President of India Inaugurated Ayush Wellness Clinic & A Restored Clock Tower at President's Estate. Available at <http://pib.nic.in/newsite/PrintRelease.aspx?relid=123746>. Accessed on 09/11/2017.
3. Bakshi BMA, Thakur T, Hasan I, Shahi VK. Model AYUSH Wellness Clinic at President's Estate, Paripex India. Indian Journal of Research. Volume-6, Issue-11, Nov. 2017, page 120-122.